

## **Post-Irradiation Orbital Deformities: Analysis of the Complex Problem and a Suggested Comprehensive Classification**

AYMAN A. SHAKER, M.D.

*The Department of Plastic and Reconstructive Surgery, Faculty of Medicine, Ain Shams University.*

### **ABSTRACT**

Post-irradiation orbital deformities are the results of removal of any malignant tumour of the orbital structures and post-operative irradiation especially in childhood. These deformities are in the form of soft tissue manifestations with or without skeletal manifestations. There are many surgical techniques for management of such deformities. However, there is no definite classification that describes the whole deformity and in turn can be used as a guide for treatment. In this paper, the clinical and radiological data of 32 patients in the different age groups were analyzed. We suggested a new system for classification of these deformities which is the SKBOE system (S): refers to soft tissue manifestations and it is further classified into S<sub>1</sub> and S<sub>2</sub> according to the presence or absence of eyelids (K): refers to skeletal manifestations and is further classified into K<sub>0</sub>, K<sub>1</sub>, K<sub>2</sub>, K<sub>3</sub> according to the degree of hypoplasia of the orbitozygomatic region and the presence of associated maxillary or mandibular hypoplasia (B): refers to the presence of bone defects and it is further classified into B<sub>0</sub> and B<sub>1</sub> (O): refers to the presence of osteomyelitis and is further classified into O<sub>0</sub> and O<sub>1</sub> (E): refers to the presence of the eyebrow and is further classified into E<sub>1</sub> and E<sub>2</sub>. This classification determines exactly what is missing and need to be reconstructed and in turn can outline the required management. However, other factors have to be considered, the age of the patient and his fitness for surgery, the patient's desire and previous attempts of reconstruction. This paper describes also the different techniques used for management of such type of deformities and the difficulties encountered during reconstruction.

### **INTRODUCTION**

Irradiation of the orbit is a standard procedure following enucleation or exenteration for treatment of malignant tumours of the orbital cavity [1].

There is no doubt about the effect of radiation on the orbital growth. This effect is related mainly to the age at which irradiation is given and this is defined at 6 months of age [2]. How-

ever, Hintschich et al. [3] found that this effect is more related to the time interval since enucleation than the age at enucleation.

Irradiation is not only limited to the bony orbit but also to the surrounding tissues [4-6]. This can result in varying degrees of facial deformity. In the established deformity, the skull, orbit, facial bones, orbital contents and facial soft tissues are involved. In addition to the widespread deformity in this highly visible area, there are the significant effects of post irradiation ischemia and the problems of healing associated with this [7]. The treatment of these deformities is difficult and complicated due to extensive loss of conjunctiva, deep scar formation, depression of the orbital floor, atrophy of the orbital fat and in some cases, the loss of palpebral skin. Severe depression deformity of the orbit and zygomatic region also adds to the difficulty of the problem [8].

The treatment will entail reconstruction of an adequate bony orbit, eyelids of adequate length and provision of a capacious upper and lower cul-de-sac, which is one of the most frustrating tasks in plastic surgery [9].

Many techniques were described for management of such deformities. Multi-stage procedures are usually required. Marques et al. [10] described a three stage technique, in the first operation the orbit is filled with temporalis muscle or free flap, in the second the orbital rims and eyelids are shaped and in the third a cavity for static eye prosthesis is created. Jackson et al. [7] described a two-stage technique, in the first stage total skeletal and soft tissue correction is done by frontotemporal expansion with repositioning of

the skull base area, orbital expansion and repositioning together with maxillary and mandibular surgery. Bone grafts should be inlay rather than onlay and soft tissue should be supplied by free tissue transfer. Split thickness skull grafts were preferred by them. The second stage is designed to reconstruct the socket and the eyelids by skin graft or buccal mucosal graft to allow more satisfactory rehabilitation with an ocular prosthesis. Another two-stage technique was described by Altintas et al. [11] where they used a prefabricated island temporalis fascial flap covered by full thickness skin graft for eye socket reconstruction.

One-stage techniques were also described for management of these deformities. Atabay et al. [12] used the temporalis muscle flap for orbital filling simultaneously with a prefabricated frontal island flap lined by split thickness skin graft for eye socket and eyelids reconstruction.

Another one-stage procedure was described for reconstruction of the contracted eye socket and orbitozygomatic hypoplasia by Mu et al. [13]. They used two flaps simultaneously, one of them is the temporal fascial flap which will cover a hydroxyapatite implant to provide it with a blood supply and to improve the subcutaneous contour in the orbitozygomatic area. The second one is the post auricular island skin flap for lining of the eye socket.

Lee et al. [14] also described a single-stage procedure in which surgical expansion of the contracted bony orbit is done by osteotomy with temporalis muscle transfer. The gaps in the supra and infra orbital rims and zygomatic body are filled with inlay rib grafts and for more augmentation onlay rib graft is applied over the periorbital region. A custom made silastic conformer is completely covered with the graft material and is then placed into the socket.

The aim of this paper is to address the problem of post irradiation orbital deformities trying to describe and classify these deformities. The management of such type of deformities will be outlined accordingly.

## PATIENTS AND METHODS

Thirty two patients presented with post irradiation orbital deformities. There were 18 males and 14 female patients. Sixteen of them (50%)

were in the first decade of life and 8 patients (25%) were in the second decade and the other 8 patients (25%) were in the third to fifth decade (Table 1).

Table (1): Age distribution of patients presented with post irradiation orbital deformities.

Age (years)	Number of patients	Percent (%)
0-9	16	50
10-19	8	25
20-29	3	9
30-39	2	7
40-49	3	9

Seventy percent of the patients (22 patients) had their irradiation at the age from 3 to 8 years. Thirty percent of the patients (10 patients) received irradiation at a relatively older age. The shortest interval between irradiation and presentation was 3 years and the longest interval was 21 years.

The underlying pathology was retinoblastoma in 22 patients, optic nerve glioma in 6 patients and rhabdomyosarcoma in 4 patients. Irradiation therapy was applied for all patients and additional chemotherapy was applied for 7 of them. One patient with retinoblastoma had recurrence after socket reconstruction with skin graft and was lost in the follow up. Another patient with optic nerve glioma had recurrence twice before presentation to us where repeated excisions were done.

During initial examination, all of the patients were complaining of the cosmetic deformity. None of them was able to use an ocular prosthesis. All adult patients had used ocular prostheses previously, but they were unable to use them any more because of socket contraction. Twenty seven patients had undergone various surgical procedures to reconstruct the contracted eye socket before, but the results were not satisfactory. The number of previous operations ranged from one to four.

All patients were evaluated clinically. Radiological evaluation by plain X-rays and C.T scanning of orbital and periorbital region was done for those patients having any sort of bone affection:

*Clinical evaluation included the followings:*

- The presence or absence of the eyelids, the state of the eyelids when they were present and the state of fornices.
- The supra-tarsal sulcus fullness.
- The degree of socket contracture.
- The width and shape of the palpebral fissure.
- The eyebrows.
- The peri-orbital soft tissue.
- The bony orbit.
- Signs of osteomyelitis.
- Other facial bones mainly the zygoma, maxilla and mandible.
- Possible donor areas and evidence of previous surgery.

*Radiological assessment included the following:*

- Degree of hypoplasia affecting the orbit and the other facial bones.
- Any bone loss or defect.
- The presence of osteomyelitis.

## RESULTS

Post irradiation orbital deformities may be in the form of soft tissue manifestations with or without skeletal manifestations.

*Soft tissue manifestations (S):* Were present in all patients and were classified according to the presence or absence of eyelids into two groups:

*First group (S<sub>1</sub>):*

It included 25 patients (78%) in whom the eyelids were preserved. These patients had a socket but it is contracted. The degree of socket contracture varied from mild (4 patients) to severe (21 patients). The fornices were shallow and in some cases there was no fornix at all especially the upper one due to inversion of the upper eyelid and its adherence to the floor of the socket. The palpebral fissure was narrow in 7 patients and rounded in two of them. The supra-tarsal sulcus fullness was nearly normal in 5 patients, minimally depressed in 11 patients and severely depressed in 9 patients. The orbit was severely shallow in 13 patients with mild to moderate shallowness in 12 patients. The eyebrows were normal (E<sub>0</sub>). The periorbital soft tissue was normal in 6 patients and had variable degree of hypoplasia in 19 patients (Figs. 1-4).

*Second group (S<sub>2</sub>):*

It included 7 patients (22%) in whom the eyelids were not preserved. These patients had no socket at all with replacement of the palpebral and periorbital skin by thin, fibrotic, ulcerating adherent scar, may be with discharging sinuses. In three cases a part from the eyebrow was lost (E<sub>1</sub>). The periorbital soft tissue was hypoplastic in all cases (Figs. 5-7).

*Skeletal manifestations (K):* Were not present in all patients and were classified into 4 grades:

*Grade (K<sub>0</sub>):* There was no or mild bony hypoplasia of the orbitozygomatic area. This was seen in 10 patients of the first group (S<sub>1</sub>) in whom irradiation was given at a relatively old age (Fig. 1).

*Grade (K<sub>1</sub>):* There was moderate hypoplasia. This was seen in 12 patients of the first group (S<sub>1</sub>) and one patient of the second group (S<sub>2</sub>) (Figs. 2,5,6).

*Grade (K<sub>2</sub>):* There was severe hypoplasia. This was seen in 3 patients of the first group (S<sub>1</sub>) and 6 patients of the second group (S<sub>2</sub>) (Fig. 3).

*Grade (K<sub>3</sub>):* If the hypoplasia is associated with maxillary and/or mandibular affection. This was seen in 2 patients of the first group (S<sub>1</sub>) and in 2 patients of the second group (S<sub>2</sub>) (Fig. 7).

According to the presence of bone defects (B), the patients were classified into 2 categories:

B<sub>0</sub>: There was no bone defect.

B<sub>1</sub>: There was a bone defect. This was seen in only 2 patients. One of them was in group S<sub>1</sub> and the defect was due to removal of a part from the bony framework of the orbital and periorbital region during the time of initial tumour resection without subsequent replacement (Fig. 4). The other one was in group S<sub>2</sub> and the defect was due to previous attempt of reconstruction by lamellar split of the zygoma with subsequent bone resorption (Fig. 7).

According to the presence of osteomyelitis of the orbital bone (O), the patients were classified into 2 categories:

O<sub>0</sub>: There was no osteomyelitis.

O<sub>1</sub>: There was osteomyelitis of the underlying bone. This was commonly seen in group S<sub>2</sub>

where 3 patients (43%) were presented with bone exposure and multiple discharging sinuses through the overlaying adherent scars (Fig. 6).

#### *Treatment plan:*

##### *First group ( $S_1$ ) (25 patients):*

The aim of treatment in this group is to reconstruct the already present but contracted socket.

##### *Soft tissue reconstruction:*

Four modalities for lining the socket were used [15]:

- Thick split thickness skin grafts in 4 patients.
- Full thickness skin grafts in 5 patients.
- Temporo-parietal fascial flaps and split thickness skin grafts in 4 patients.
- Retro-auricular temporal flaps in 12 patients.

In the follow up period, 5 patients required filling of the supra-tarsal sulcus depression by non vascularized dermofat graft. Another 2 patients required lateral canthoplasty to correct the round palpebral fissure (Fig. 8). Another one patient who was reconstructed by a retro auricular temporal flap needed further medial canthotomy and release of the medial part of the upper eyelid and lining by full thickness skin graft.

##### *Skeletal reconstruction:*

In patients having no or mild hypoplasia (10 patients) no interference was required. In patients having moderate hypoplasia (12 patients), only 5 of them requested augmentation of the orbitozygomatic area. This was done in a separate stage by the use of non vascularized dermo-fat graft from the groin. In patients having severe hypoplasia (3 patients), two of them requested reconstruction. In the first one it was done by deepithelialized vascularized anterolateral thigh flap. The second one had associated loss of a part from the frontal bone, roof of the orbit, supra-orbital and lateral orbital ridges in the previous resection. The cranial bone defect was reconstructed by inlay calvarial bone graft. The supra-orbital and lateral orbital ridges were reconstructed by inlay rib grafts. Further augmentation of the orbitozygomatic area was done by onlay split rib grafts. In this particular case, the whole socket and eyelids were released from the underlying fibrosis with filling of the orbit with non vascularized temporalis fascia graft to

prevent readherence of the eyelids. Reconstruction of the socket itself was planned to be done by a retro-auricular temporal flap, but due to technical problem during flap elevation, this was postponed to another stage (Fig. 9).

##### *Second group ( $S_2$ ) (7 patients):*

The aim of treatment in this group is to replace the unstable adherent scarring with a healthy well vascularized tissue that will be used later on for creation of the new socket.

##### *Soft tissue reconstruction:*

In one patient the scar itself was not so bad and it was splitted transversely to create the socket that was lined by a retroauricular temporal flap. In two patients the scars were completely excised and replaced by retro-auricular temporal flap with lining of the socket by thick split thickness skin graft. In another 2 patients with exposure and osteomyelitis of the underlying bone, the necrotic bone was debrided and socket reconstruction was done by the use of temporalis muscle flap and split thickness skin graft [16]. The flap was used to fill the orbital cavity and to cover the exposed bones. The graft was used to cover the muscle and reflected to line the undersurface of the retro-auricular temporal flap which will be divided later on to create both eyelids. In one of these 2 patients half of the retroauricular temporal flap sloughed from venous congestion and reconstruction was done later on using the free radial forearm flap. In the last two patients the scars were replaced by a free radial forearm flap. Anastomosis was done with the neck vessels.

##### *Skeletal reconstruction:*

One patient had moderate hypoplasia of the orbitozygomatic area and did not request reconstruction. Six patients had severe hypoplasia, three of them had also exposure and osteomyelitis of the underlying bone and in one of them there was missing of a part from the bone.

In two patients the bony framework was reconstructed by multiple split rib grafts as onlay grafts to augment and as inlay grafts to replace and augment the missing bone and covered by the free radial forearm flap. Later on in the follow up complete resorption of the free bone grafts occurred and camouflaging the hypoplasia was done by the use of vascularized anterolateral thigh dermofat flap anastomosed to the neck vessels (Fig. 10).



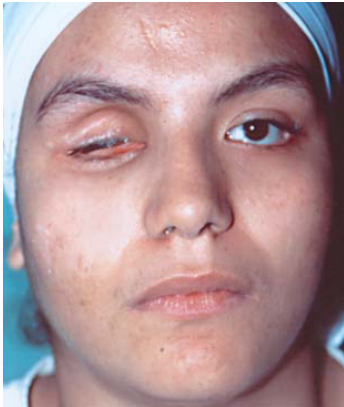

Fig. (1): Patient classified as S<sub>1</sub> K<sub>0</sub> B<sub>0</sub> O<sub>0</sub> E<sub>0</sub>: Eyelids are present, no bone hypoplasia or defect or osteomyelitis with normal eyebrow.

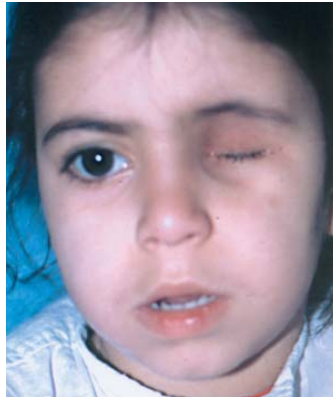

Fig. (2): Patient classified as S<sub>1</sub> K<sub>1</sub> B<sub>0</sub> O<sub>0</sub> E<sub>0</sub>: Eyelids are present, moderate hypoplasia, no bone defect or osteomyelitis with normal eyebrow.

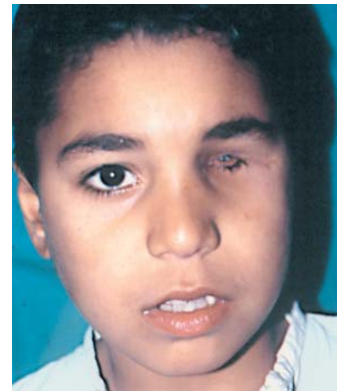

Fig. (3): Patient classified as S<sub>1</sub> K<sub>2</sub> B<sub>0</sub> O<sub>0</sub> E<sub>0</sub>: Eyelids are present, severe hypoplasia, no bone defect or osteomyelitis with normal eyebrow.

Fig. (4)

A- Patient classified as S<sub>1</sub> K<sub>2</sub> B<sub>1</sub> O<sub>0</sub> E<sub>0</sub>: Eyelids are present, moderate hypoplasia, bone defect, no osteomyelitis with normal eyebrow.

B- C.T. scan of the same patient showing the hypoplasia and bone defect.

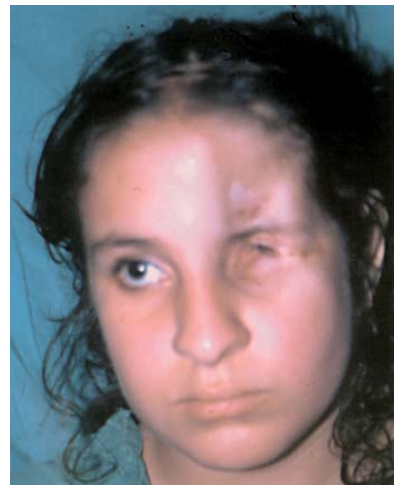

Fig. (4-A)

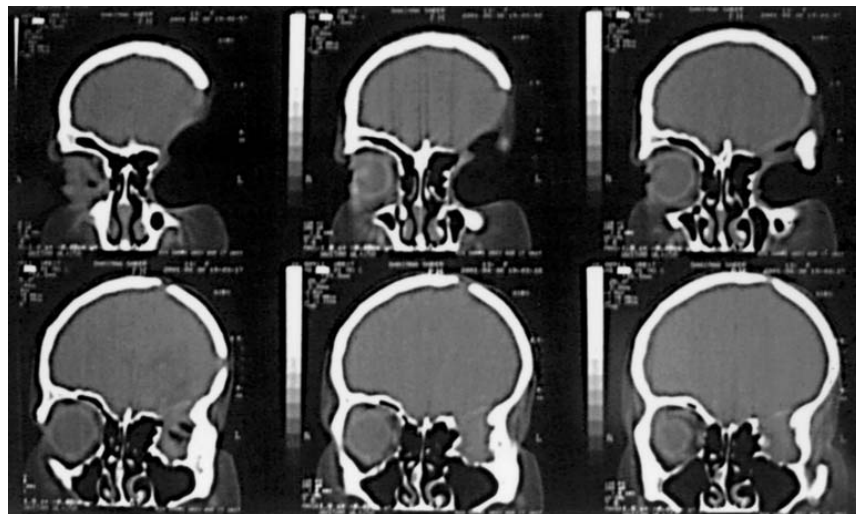


Fig. (4-B)

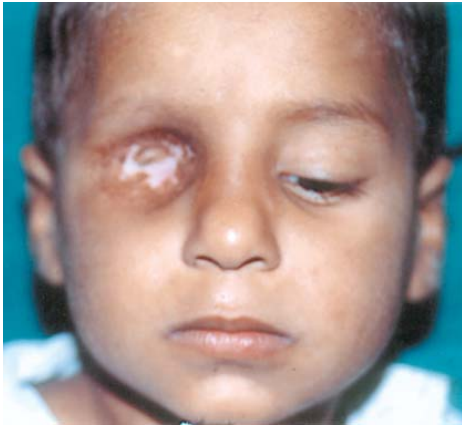

Fig. (5): Patient classified as S<sub>2</sub> K<sub>1</sub> B<sub>0</sub> O<sub>0</sub> E<sub>0</sub>: Eyelids are not present, moderate hypoplasia, no bone defect or osteomyelitis with normal eyebrow.

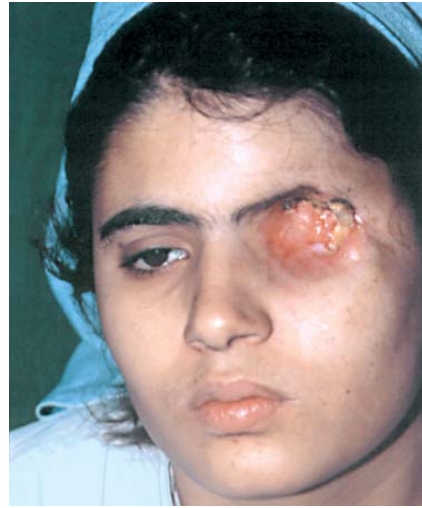

Fig. (6): Patient classified as S<sub>2</sub> K<sub>1</sub> B<sub>0</sub> O<sub>1</sub> E<sub>1</sub>: Eyelids are not present, moderate hypoplasia, no bone defect, osteomyelitis with loss of a part from the eye brow.

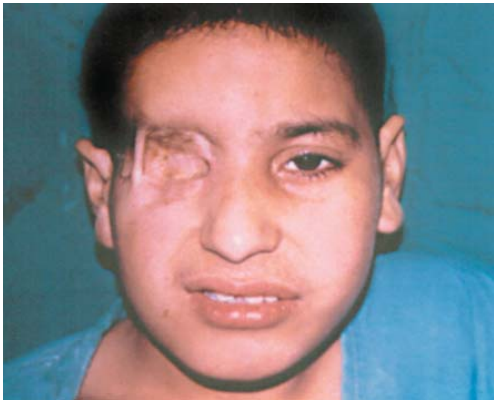

Fig. (7): Patient classified as S<sub>2</sub> K<sub>3</sub> B<sub>1</sub> O<sub>1</sub> E<sub>1</sub>: Eyelids are not present, severe hypoplasia associated with maxillary hypoplasia, bone defect, osteomyelitis with loss of a part from the eye-brow.

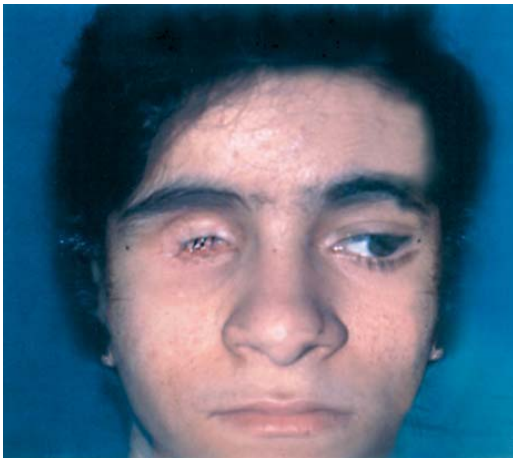

Fig. (8-A): Pre-operative view of patient classified as S<sub>1</sub> K<sub>1</sub> B<sub>0</sub> O<sub>0</sub> E<sub>0</sub>.

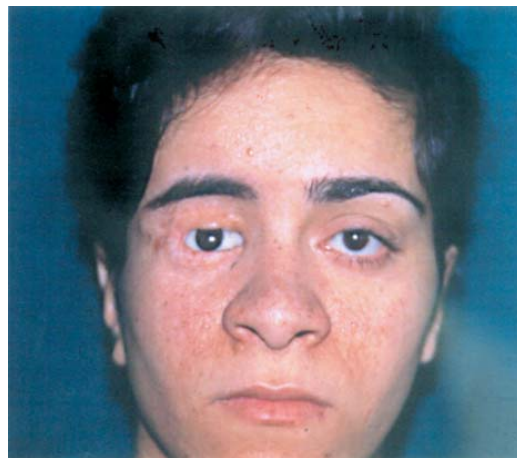

Fig. (8-B): Post-operative view after socket reconstruction by retro-auricular temporal flap, lateral, augmentation of the supra-tarsal sulcus depression and zygomatico-orbital region by non-vascularized dermofat graft.

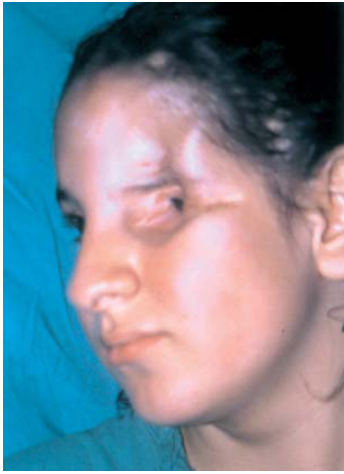

Fig. (9-A): Pre-operative lateral view of patient classified as S<sub>1</sub> K<sub>2</sub> B<sub>1</sub> O<sub>0</sub> E<sub>0</sub> (Fig. 4).

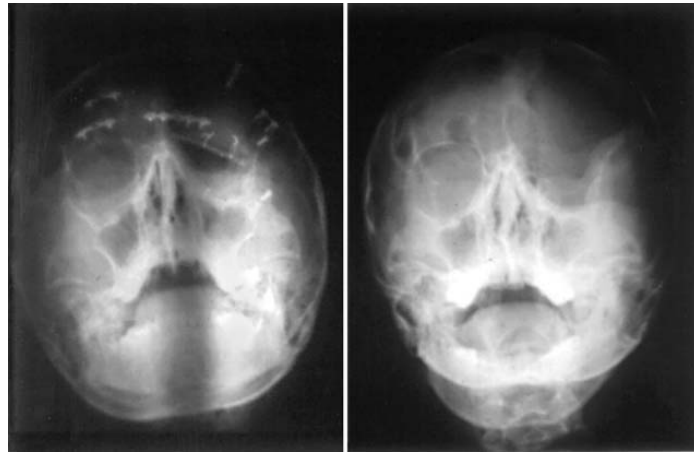


Fig. (9-D): Pre- and post-operative X-ray.

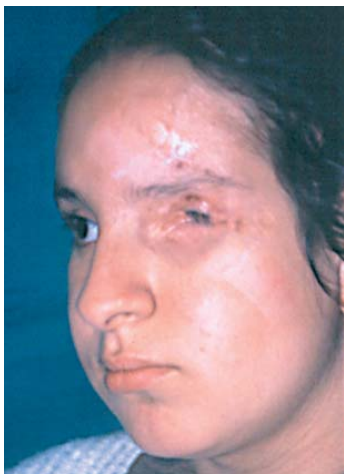

Fig. (9-B): Post-operative view.

Fig. (10-A): Post-operative view of patient classified as S<sub>2</sub> K<sub>2</sub> B<sub>1</sub> O<sub>1</sub> E<sub>1</sub> (Fig. 7), after reconstruction by inlay split rib grafts, radial forearm flap and deepithelialized antero-lateral thigh flap.

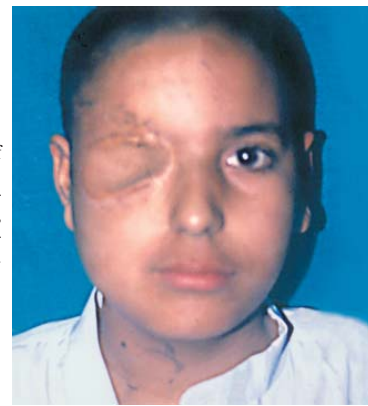

Fig. (10-B): C.T. scan of same patient showing the pre-operative defect, the bone reconstruction and the complete bone resorption 2 years post-operatively.

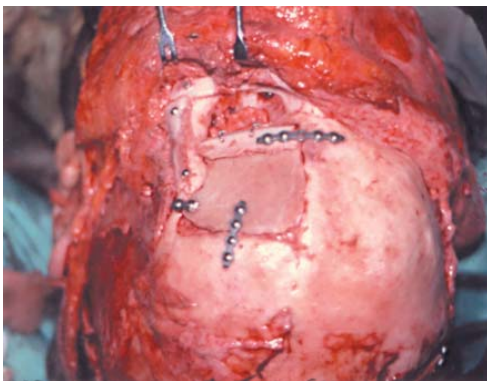
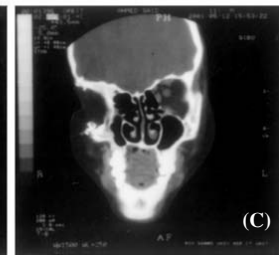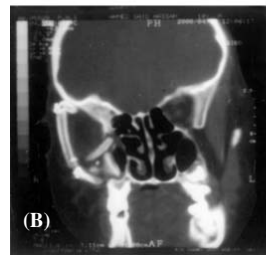
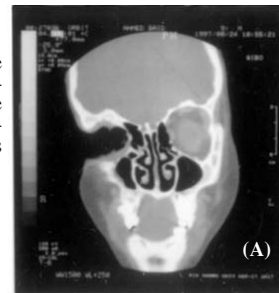


Fig. (9-C): Intra operative view showing the bony work.



## DISCUSSION

Post-irradiation orbital deformities are the results of removal of any malignant tumour of the orbital structures and post-operative irradiation especially in childhood. The magnitude of the deformity depends mainly on many factors; the primary surgical procedure, the age at which irradiation is given [2] and the time interval since enucleation or exenteration [3]. Though this age was defined to be 6 months [2], we found that, even when irradiation was given at the age of 3-8 years still there is a variable degree of hypoplasia. Late presentation of patients in this series was explained by repeated attempts of previous reconstruction elsewhere.

These deformities are variable and many techniques were described for their management. Multi-stage procedures are usually required [7,10,11], but one-stage techniques were also described [12-14]. Some of these techniques handle the problem of socket reconstruction without addressing the bony problem [8,11,15-27]. Other techniques handle the problem of soft tissue and bone deficiency [7,13,14]. There is no single report that describes the whole deformity and its full correction. However, the report of Jackson et al. [7] was the only one which nearly covered most aspects of correction. Their treatment concept included four basic principles: First, the face is frequently deformed at all four levels: cranial, orbital, maxillary and mandibular. Second, this affects bone and soft tissue in a three-dimensional fashion. Third, osteotomies with inlay bone grafts are performed rather than onlay bone grafts, since the latter simply fade away within a short time. Fourth, when indicated to provide soft tissue and combat post-irradiation ischemia, vascularized free tissue transfer is preferred.

In this paper we tried to put a standard classification for post irradiation orbital deformities which in turn will be a guide for the treatment plan. Many factors affect the plan of reconstruction including the presence or absence of the eyelids, the degree of contracture and fibrosis of the socket, the degree of soft tissue and bone hypoplasia, the presence of underlying bone defect or osteomyelitis, age of the patient and his fitness for surgery, the patient's desire and previous attempts of reconstruction.

These deformities may be in the form of soft tissue manifestations (S) with or without skeletal

manifestations (K). Soft tissue manifestations can be further classified into  $S_1$ ,  $S_2$  according to the presence or absence of eyelids. Skeletal manifestations can be classified according to the degree of hypoplasia into  $K_0$ ,  $K_1$ ,  $K_2$ ,  $K_3$ . According to the presence of bone defect, the deformities can be classified into  $B_1$ ,  $B_2$ . According to the presence of osteomyelitis, the deformities can be classified into  $O_0$ ,  $O_1$ . According to the presence of the eyebrow, the deformities can be classified into  $E_0$ ,  $E_1$ .

So, we suggest the SKBOE system for classification of these deformities. The simplest deformity is  $S_1 K_0 B_0 O_0 E_0$  which is in the form of just contracted eye socket without any underlying bone affection and this was seen in 10 patients in whom irradiation was given at a relatively old age. The severest deformity is  $S_2 K_3 B_1 O_1 E_1$  which is in the form of loss of both eyelids with no socket with severe hypoplasia of the orbit-zygomatic area, maxilla and mandible and underlying bone defect with osteomyelitis and loss of a part from the eyebrow. This was seen in only one patient.

Before planning the treatment, anatomic assessment of the deformity has to be done, then the selection of the reconstructive procedure will depend on the specific deformities that the patient has [14].

$S_1$  deformities are reconstructed as any socket reconstruction. Various materials were described for lining of the socket including conventional skin graft [17], mucosal graft [18], temporalis muscle flap [16,19-23], temporoparietal fascial flap [11,24], retro-auricular temporal flap [15,25,26] and free flap [8,27]. Also, a combination of two of these materials was used for simultaneous orbital filling and socket reconstruction [12].

In a previous report [15], the retro-auricular temporal flap was found to be the best material used to guard against recurrence of socket contraction. However, it is a demanding procedure as regards operative time, number of operations and it needs tedious post-operative monitoring and secondary procedures for flap fashioning. Skin grafts are used only in mild cases of socket contraction without any fibrosis of the periorbital region and in elderly patients who could not withstand more sophisticated procedures. However, they have a high percent of recurrence of socket recontraction. The temporo-parietal fascial



flaps [24] can provide a socket with adequate size and volume without secondary graft shrinkage when they are prefabricated by full thickness skin grafts [11]. However, their uses without prefabrication is usually associated with high percent of socket recontraction [15].

Some minor revision operations were also required during the follow up period including augmentation of the supra-tarsal sulcus depression by dermofat graft, further release of the fornix with full thickness skin graft if it is still shallow and lateral canthoplasty. Other minor procedures that may be also required, full thickness graft for ectropion and a fascia suspension for drooping of the orbital fissure [14].

In S<sub>2</sub> deformities the situation is completely different as there is no eyelids or socket. In such a case there is no role for mucosal grafts or skin grafts with their different types. So, the thin ulcerating adherent scarring has to be replaced and covered by a well vascularized tissue including either the temporalis muscle flap [16,19-23], retro-auricular temporal flap [15,25,26] or free flap [27]. Temporalis muscle flap is only used when there is bone exposure and osteomyelitis with excessive hollowness of the orbit and it is mainly used for coverage of the exposed bone and orbital filling and has to be covered by another retro-auricular temporal flap for eyelid reconstruction. Free flaps are not used except when the temporalis muscle flap and the retro-auricular temporal flap are not feasible or if they are indicated for correction of the underlying soft tissue and bone hypoplasia. The radial forearm flap provides the best color match and thickness for eyelid reconstruction. However, it has no sufficient bulk to augment cases with severe hypoplasia.

Skeletal deformities (K) may be in the form of hypoplasia, bone loss or osteomyelitis or combination of all. Many techniques were described for treatment of these deformities. However, they differ in the way of reconstruction of bony deficiency. Some authors advocated frontotemporal expansion, orbital expansion and reposition of the skull base area and the orbit by inlay bone grafts [7]. Others recommended surgical expansion of the contracted orbit with inlay grafts for the defects and further augmentation by onlay bone grafts [14]. Others did not recommend any sort of osteotomy, but advised

camouflage augmentation by hydroxyapatite [13].

No or mild hypoplasia (K<sub>0</sub>) is usually accepted by the patient and they do not require any sort of reconstruction. Onlay grafting of the underlying bone is usually followed by complete resorption due to the effect of irradiation. This happened in some cases even when these bones were covered by well vascularized tissues. For this reason, the use of this type of grafting should be limited. For patients with moderate hypoplasia (K<sub>1</sub>) who requested correction, we preferred to use the non-vascularized dermo-fat graft as a camouflage procedure. For patients with severe hypoplasia (K), osteotomy with inlay grafts can give good results as inlay grafts survive better than onlay grafts [7]. This osteotomy can be done either by fronto-temporal expansion and orbital expansion [7] or by orbital expansion only [14]. Although the split thickness skull grafts was preferred by Jackson et al. [7], Lee et al. [14] did not recommend its use. They found it not very good choice as bone graft material as the calvarium became sclerotic after radiation treatment. The most significant point is that these osteomized bones and bone grafts have to be covered by well vascularized tissues. Though the temporaries muscle flap was recommended by Lee et al. [14], Jackson et al. [7] preferred to use a free tissue transfer to bring increased vascularity into this relatively ischemic area.

Another method of treating severe hypoplasia is camouflaging procedure by either foreign material like hydroxyapatite [13] or autogenous tissues [7,8]. Despite of claims of success with the use of foreign material [13], Jackson et al. [7] preferred to use autogenous tissue for augmentation due to the effect of post irradiation ischemia. The vascularized deepithelialized anterolateral thigh flap was used successfully in some cases. It can provide a good bulk and at the same time it has a long vascular pedicle with minimal donor site morbidity. In cases of deficient superficial temporal vessels-which is common-due to its previous use in one of the reconstructive procedures or due to the effect of radiation, the anastomosis has to be done with the neck vessels. For this reason a flap with a long vascular pedicle is required.

If there is associated maxillary and/or mandibular affection (Grade K<sub>3</sub>), the suitable reconstructive procedures have to be done [7].

eyebrow affection may be present and has to be dealt with. The only paper that referred to this was that of Marques et al. [10]. They could not use the classic converse biological flap since the superficial temporal vessels had already been used to receive a free flap. Strip and punch grafts could not be also used due to the precarious blood supply of the area. So, it is preferable to use small hair grafts like the single hair transplant [27].

In conclusion, post irradiation orbital deformities are variable. Thorough analysis of the deformity is crucial before planning the treatment. For this analysis a system for classification is required and it can be used as a guide for the treatment. The management of these deformities is difficult as it entails reconstruction of more than one structure and usually require multi-stage operations. The relative ischemia of the area, the deficient superficial temporal vessels and the tendency for bone resorption are other factors that add to the difficulty of reconstruction. Vascularized tissue like temporalis muscle, retroauricular temporal flaps and free flaps are better than free grafts with their different types. Free flaps are not only used for skin replacement but also for camouflage augmentation of the underlying bony hypoplasia to avoid the problem of bone resorption.

## REFERENCES

- 1- McGinnis J.P., Hopkins K.P., Thompson E.I. and Hustu H.O.: Mandibular third molar development after mantle radiation in long-term survivors of childhood Hodgkin's disease. *Oral. Surg.*, 63: 630, 1987.
- 2- Imhof S.M., Mourits M.P., Hofman P., et al.: Quantification of orbital and mid-facial growth retardation after megavoltage external beam irradiation in children with retinoblastoma. *Ophthalmology*, 103: 2, 1996.
- 3- Hintschich C., Zonneveld F., Baldeschi L., et al.: Bony orbital development after early enucleation in humans. *Br. J. Ophthalmol.*, 85: 2, 2001.
- 4- Jaffe N., Toth B.B., Hoar R.E., et al.: Dental and maxillofacial abnormalities in long-term survivors of childhood cancer: Effects of treatment with chemotherapy and radiation to the head and neck. *Pediatrics*, 73: 816, 1984.
- 5- Larson E.P.: Long-term effects of radiation therapy in the head and neck. *Clin. Plast. Surg.*, 20: 485, 1993.
- 6- Parsons J.T.: The effect of radiation on normal tissues of the head and neck. In R.R. Million and N.J. Cassisi (Eds). *Management of head and neck cancer: A multidisciplinary approach*, Philadelphia: Lippincott, 1994.
- 7- Jackson I.T., Carls F., Bush K., et al.: Assessment and treatment of facial deformity resulting from radiation to the orbital area in childhood. *Plast. Reconstr. Surg.*, 98: 1169, 1996.
- 8- Asato H., Harii K., Yamada A. and Ueda K.: Eye socket reconstruction with free-flap transfer. *Plast. Reconstr. Surg.*, 92: 1061, 1993.
- 9- Wolfe S.A.: Surgical reconstruction of the contracted orbit (Discussion). *Plast. Reconstr. Surg.*, 103: 1137, 1999.
- 10- Marques A., Brenda E., Magrin J., et al.: Critical analysis of methods of reconstruction of exenterated orbits. *Br. J. Plastic. Surg.*, 45: 523, 1992.
- 11- Altintas M., Aydin Y. and Yucel A.: Eye socket reconstruction with the prefabricated temporal island flap. *Plast. Reconstr. Surg.*, 102: 980, 1998.
- 12- Atabay K., Ataby C., Yavuzer R., et al.: One-stage reconstruction of eye socket and eyelids in orbital exenteration patients. *Plast. Reconstr. Surg.*, 101: 1463, 1998.
- 13- Mu X., Dong J. and Change T.: Surgical reconstruction of the contracted eye socket and orbitozygomatic hypoplasia in a one-stage operation. *Plast. Reconstr. Surg.*, 103: 487, 1999.
- 14- Lee Y.H., Kim H.C., Lee J.S., et al.: Surgical reconstruction of the contracted orbit. *Plast. Reconstr. Surg.*, 103: 1129, 1999.
- 15- Shaker A.A.: Modalities of contracted eye socket reconstruction. *Egyptian J. Plast. Reconstr. Surg.*, 22: 203, 1998.
- 16- Reese A.B. and Jones L.S.: Exenteration of the orbit and repair by transplantation of the temporalis muscle; a modification of Reese's technique. *Am. J. Ophthalmol.*, 68: 18, 1961.
- 17- Antia N.H. and Arora S.: "Malignant" contracture of the eye socket. *Plast. Reconstr. Surg.*, 74: 292, 1984.
- 18- Petrelli R.L.: Management of the contracted eye socket. *Int. Ophthalmol.*, 5: 33, 1982.
- 19- Byrd H.S.: The use of subcutaneous axial fascial flaps in reconstruction of the head. *Ann. Plast. Surg.*, 4: 191, 1980.
- 20- Tessier P. and Krastinova D.: La transposition du muscle temporal dans L'orbitale anophtalme. *Ann. Chir. Plast.*, 27: 212, 1982.
- 21- Bosniak S., Sacks and Smith B.: Temporalis muscle transfer: Avascular bed for autogenous dermis-fat orbit implantation. *Ophthalmology*, 92: 191, 1985.
- 22- Habal M.D.: Aesthetic considerations in the reconstruction of the anophthalmic orbit. *Aesthetic Plast. Surg.*, 11: 229, 1987.
- 23- Menderes A., Yilmaz M., Vayvada H., et al.: Reverse temporalis muscle flap for the reconstruction of orbital exenteration defects. *Ann. Plast. Surg.*, 48: 521, 2002.

- 24- Ellis D.S., Toth B.A. and Stewart W.B.: Temporo-parietal fascial flap for orbital and eyelid reconstruction. *Plast. Reconstr. Surg.*, 89: 606, 1992.
- 25- Guyuron B.: Retroauricular island flap for eye socket reconstruction. *Plast. Reconstr. Surg.*, 76: 527, 1985.
- 26- Van der Meulen C.: Reconstruction of a socket using a retro-auricular temporal flap. *Plast. Reconstr. Surg.*, 75: 112, 1985.
- 27- Tahara S. and Susuki T.: Eye socket reconstruction with free radial forearm flap. *Ann. Plast. Surg.*, 23: 112, 1989.
- 28- Choi Y.C. and Kim J.C.: Single hair transplantation using the Choi Hair Transplanter. *J. Dermatol. Surg. Oncol.*, 18: 945, 1992.